



PATIENT

Hendricks
Dombrowski

SPECIES

Feline

BREED

Cornish Rex

SEX

Male Neutered

AGE

1 year

WEIGHT

9.3Lbs

INTERPRETED BY

Maggie Machen Lamy,
DVM DACVIM
(Cardiology)

**IMAGING
PERFORMED BY**

Kelly Reschny, RVT

HOSPITAL NAME

Halton Peel Animal
Hospital

REFERRING VET

Dr. Walters

INVOICE

27174

DATE

10/28/22

PRESENTING CLINICAL SIGNS

History: Arrhythmia, pause in heart sound every 2-3 beats.

ELECTROCARDIOGRAPHIC FINDINGS *Note: Single lead ECGs are evaluated as a rhythm strip. Morphology/MEA cannot be definitively commented on.

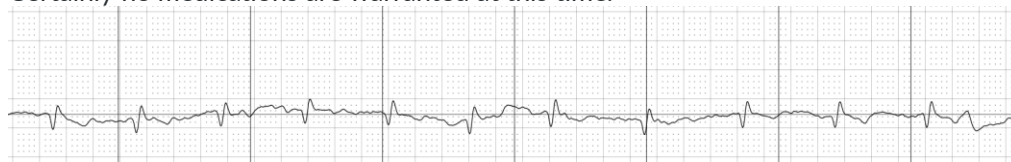
A single lead ECG is available; 50mm/s, 20mm/mV. The average heart rate is 180bpm (range 176-200bpm). The rhythm is sinus in origin, with a p for every QRS complex and vice versa. A single premature beat is possible, although artifact is not ruled out. No pauses or other dysrhythmias observed.

ECG diagnosis: Normal sinus tachycardia with a possible premature beat.

INTERPRETATION OF THE FINDINGS & FURTHER RECOMMENDATIONS

The ECG shows a normal sinus tachycardia with a possible single premature beat. This is only suspect as a single lead tracing is highly insensitive, and artifact is also possible. Consider an extended tracing or potentially a 6 lead ECG if the auscultated abnormality persists. If present, premature beats may be primary in origin, secondary to cardiac disease, or develop secondary to stress, systemic disease, pain, etc. Further cardiac and systemic evaluation may be warranted in a young cat.

Certainly no medications are warranted at this time.



IMAGES

The information and recommendations provided are based on the images presented by the referring veterinarian. No evaluation can be communicated regarding pathology that was not visible in the image/video clips provided.

Thank you for this referral. This report was generated using transcription software, and minor dictation errors may be present. If the clinical or image interpretation does not parallel your findings or if I can be of any further assistance, please contact me.

Maggie Machen Lamy, DVM

Diplomate of the American College of Veterinary Internal Medicine (Cardiology)
info@sonopath.com